

Pancreatic Extra-Gastrointestinal Stromal Tumour with Documentation of C-Kit Mutation: A Case Report

PREETI JOSEPH¹, RICHA GOYAL², PREETI BANSAL³, RAJNI PARMAR⁴, SARJANA DUTT⁵

ABSTRACT

Gastrointestinal stromal tumours (GIST) are the most common mesenchymal neoplasms located in the alimentary tract. Stromal tumours that arise outside the gastrointestinal tract as primary tumour are designated as extra-gastrointestinal stromal tumours (EGIST). The EGIST are located in mesentery, omentum, retroperitoneum and rarely in pancreas. Only 19 cases of pancreatic EGIST (pEGIST) have been reported in the literature. Of these, there were only two cases of pEGIST with documentation of molecular alteration in C-Kit gene. We here report a third case of primary pEGIST with documentation of C-kit mutation.

CASE REPORT

A 60-year-old male presented with pain in left side of abdomen for several months. Physical examination revealed an abdominal mass in left hypochondrium. Basic laboratory investigations were non contributory. MRI scan of the abdomen showed a 21x18x14 cm solid and cystic mass lesion in relation to the body and tail of pancreas.

CT guided FNAC of pancreatic mass yielded low cellularity consisting of few round to oval atypical cells with eccentric nuclei and moderate amount of cytoplasm. The cytology was suggestive of neoplastic pathology however the definite typing was not possible. Abdominal laparoscopy was carried out which revealed a large solid and cystic mass involving body and tail of pancreas. The biopsy on histopathology examination showed a tumour composed of sheets of round to epithelioid cells with hyalinised stroma and intervening blood vessels. The tumour cells showed mild pleomorphism, oval to mildly irregular nuclei and scant to moderate amount of eosinophilic to vacuolated cytoplasm. No tumour necrosis was seen however the mitotic count was around 1/10HPF [Table/Fig-1,2]. Immunohistochemistry staining revealed diffuse cytoplasmic positivity for CD117 (c-kit) [Table/Fig-3], CD34 and variable positivity for vimentin and focal positivity for SMA. The cells were completely negative for S-100, neuron specific enolase, chromogranin A, CD99 and synaptophysin. The morphological and immunohistochemical findings were favouring epithelioid subtype of GIST. Hence, the diagnosis of pancreatic GIST with high risk of malignancy was made. Subsequently, C-kit mutation analysis was done which revealed a deletion mutation of exon 11 resulting in loss of amino acid at positions 554 to 559. Wild or normal gene sequence

Keywords: CD117, C-Kit mutation, Pancreas, pEGIST

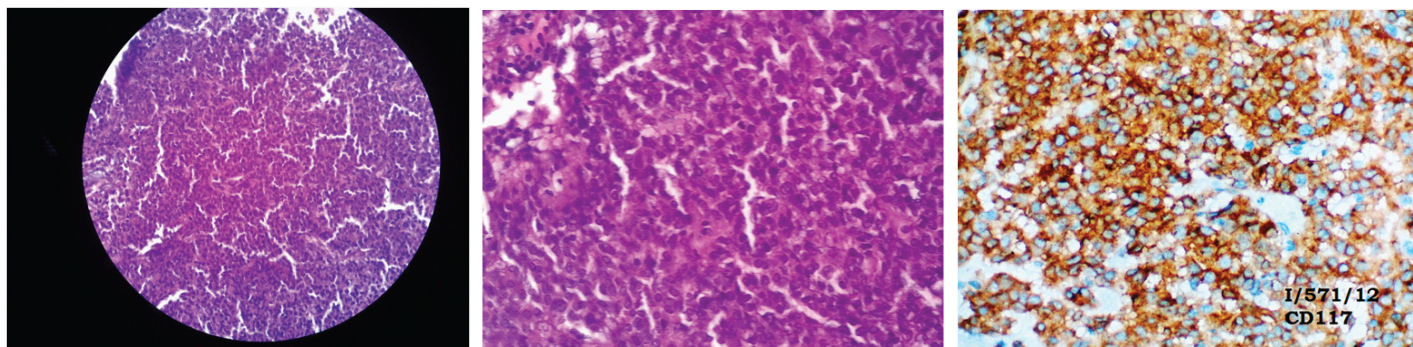
was observed in exon 9 of c-kit gene. Patient was put on imatinib therapy. Follow up MRI after 3 months showed metastatic deposits in lung and patient died within 9 months of initial diagnosis.

DISCUSSION

It is presumed that GIST's originate from the interstitial cells of cajal and express the C-kit receptor tyrosine kinase (CD117) [1]. Yamura et al., have shown the presence of c-KIT positive interstitial cells surrounding the intercalated ducts and acinus in the pancreas [2]. These cells named as pancreatic interstitial cajal like cells are now called as telocytes.

EGIST originate from the soft tissues of the abdomen and retroperitoneum such as the omentum, mesentery, retroperitoneum and gall bladder [3]. EGIST arising in the pancreas are rare neoplasm (pEGIST) and only 19 cases have been reported in the literature [4]. The age range was 38 to 84 yrs and most of the patients presented with gastric pain and abdominal mass. The index case was 60-years-old and had similar clinical presentation. The majority (42.1%) of pEGIST occurred in the head of the pancreas, 26.3% in tail, 21.1% in both body and tail and 5.3% in the uncinate process [4]. In the current case, tumour was detected in body and tail of the pancreas. The tumour ranged from 2.4cm to 35 cm in size in various studies and in present case, the maximum tumour size was 21cm.

The immunohistochemical marker for GIST is the expression of the C-kit receptor tyrosine kinase (CD117 antigen). Approximately 5% of GIST are C-Kit negative and harbour PDGFR α mutation [1]. In addition, 40 to 70 % GIST's show positivity for CD34 and variable positivity for other mesenchymal markers such vimentin, myoid (smooth muscle actin and desmin) and neural (S100) marker.



[Table/Fig-1]: Photomicrograph showing sheets of epithelioid cells with intervening stroma (H&E, X 100)

[Table/Fig-2]: Photomicrograph showing epithelioid cells with irregular nuclei and moderate amount of eosinophilic to vacuolated cytoplasm (H&E, X 400)

[Table/Fig-3]: Photomicrograph showing cytoplasmic positivity for CD117 (Immunohistochemical stain, X 400)

According to Padhi et al., 84.2% cases of pEGIST showed strong diffuse cytoplasmic positivity for CD117/c-KIT and 73.7% cases were positive for CD34 [4]. In present case, the tumour showed diffuse positivity for both CD117 and CD34. Recently DOG-1 and protein kinase C theta are said to be the most specific biomarkers of GIST/EGIST. Babu et al., recently described a case of DOG-1 positive pEGIST [5].

The c-kit mutations responsible for GIST carcinogenesis are exon 11 (most common), exon 9 (second most common), exon 13, 17 and PDGFR- alpha mutation in exon 12, 14, 18 [4]. The molecular biology of pEGIST has been documented only in two cases [6,7]. Daum et al., showed deletion of six base pairs in exon 11 of c-kit, causing loss of Glu at position 556 and Trp at position 557 of the KIT protein [6]. Saif Wasif et al., did not find c-kit mutation involving exon 11, 13, 17 and 18; however they reported DNA polymorphism of L862L in exon 18 of C-kit gene [7]. In the present case there was deletion mutation in exon 11, resulting in loss of aminoacid at position 554 to 559. Wild or normal gene sequence was observed in exon 9 of c-kit gene.

Differential diagnosis between EGIST and other mesenchymal tumour is of crucial importance as the target therapy Imatinib (Gleevec) which is an inhibitor of the tyrosine kinase activity of c-kit has revolutionized the treatment of this disease. Ursula et al., reported solid hamartoma of the pancreas showing disordered arrangement of pancreatic acini, intralobular and interlobular ducts embedded in a fibrous stroma with elongated spindle cells. Immunohistochemically CD117 and CD34 expression was seen in fibrotic stroma [8]. C-KIT mutation can helps in differentiating these hamartoma of the pancreas from the primary GIST of the pancreas.

Hou ying-yong et al., studied sequence and expression of c-kit gene in 52 cases of GIST's including benign, borderline and malignant variants from different sites [9]. Mutation of exon 11 were found

in 56% of malignant GIST's, mutation of exon 11 of the c-kit gene were revealed in 10.5% of borderline GIST's and no mutation was found in benign tumours. They concluded that C-kit mutation occur preferentially in malignant GIST's and might be a clinically useful adjunct marker in the evaluation of GIST's and can help to differentiate GIST's from the other mesenchymal tumours [9].

CONCLUSION

We presented a rare case of primary pancreatic EGIST with documentation of mutation of C-Kit gene. Further studies need to be done to know whether the c-kit gene mutation can indicate bad prognosis of malignant GISTs or not.

REFERENCES

- [1] Miettinen M, Lasota J. Gastrointestinal stromal tumours: review on morphology, molecular pathology, prognosis, and differential diagnosis. *Arch Pathol Lab Med*. 2006;130:1466-78.
- [2] Yamura K, Kato K, Miyazawa M, et al. Stromal tumour of the pancreas with expression of C-kit protein: report of a case. *J Gastroenterol Hepatol*. 2004;19:467-70.
- [3] Weiss SW, Goldblum JR. Extra gastrointestinal stromal tumours. In: Enzinger and Weiss's soft tissue tumours; fifth edition. Mosby Elsevier. 2008; Pp. 565-579.
- [4] Padhi S, Sarangi R, Mallick S. Pancreatic extragastrointestinal stromal tumour, interstitial cajal like cells, and Telocytes. *JOP. Journal of Pancreas (online)*. 2013;14(1):1-14.
- [5] Babu SR, Kumari S, Zhang Y, et al. Extra gastrointestinal stromal tumour arising in the pancreas: a case report and literature review. *J Gastroenterol Hepatol Res*. 2012;1:80-83.
- [6] Daum O, Klecka J, Ferda J, et al. Gastrointestinal stromal tumour of the pancreas: Case report with documentation of KIT gene mutation. *Virchow Arch*. 2005;446:470-72.
- [7] Saif MW, Hotchkiss S, Kaley K. Gastrointestinal stromal tumours of the pancreas. *JOP. J Pancreas (online)*. 2010;11(4):405-06.
- [8] Pauser U, Da Silva M TS, et al. Cellular hamartoma resembling gastrointestinal stromal tumour: a solid tumour of the pancreas expressing c-Kit (CD117). *Modern Pathology*. 2005;18(9):1211-16.
- [9] Hou YY, Grabelius F, Weber F, et al. Impact of KIT and PDGFR A gene mutation on prognosis of patients with gastrointestinal stromal tumours after complete primary tumour resection. *J Gastrointest Surg*. 2009;13:1583-92.

PARTICULARS OF CONTRIBUTORS:

1. Consultant, Department of Pathology, Oncquest Lab, Mohan Dai Oswal Hospital, Sherpur Chowk, Ludhiana, Punjab, India.
2. Senior Consultant, Department of Pathology, Oncquest Lab, Mohan Dai Oswal Hospital, Ludhiana, Punjab, India.
3. Senior Resident, Department of Pathology, Oncquest Lab, Mohan Dai Oswal Hospital, Ludhiana, Punjab, India.
4. Senior Consultant, Department of Pathology, Oncquest Lab, New Delhi, India.
5. Director, Molecular Biology and R & D, Oncquest Lab, New Delhi, India.

NAME, ADDRESS, E-MAIL ID OF THE CORRESPONDING AUTHOR:

Dr. Preeti Joseph,
Oncquest Lab, Mohan Dai Oswal Hospital, Sherpur Chowk, Ludhiana -141009, Punjab, India.
Email – dr_priti77@yahoo.com

FINANCIAL OR OTHER COMPETING INTERESTS: None.

Date of Submission: Jan 15, 2015
Date of Peer Review: Mar 09, 2015
Date of Acceptance: Mar 19, 2015
Date of Publishing: Apr 01, 2015